

STATE TOXINOLOGY SERVICES

Toxinology Dept., Women's & Children's Hospital, North Adelaide SA 5006 AUSTRALIA

SNAKEBITE MANAGEMENT OVERVIEW DOCUMENT

www.toxinology.com record number SN0379

Family Scientific name combined
Viperidae *Bothriechis schlegelii*
Common name
Eyelash Palm Pit Viper

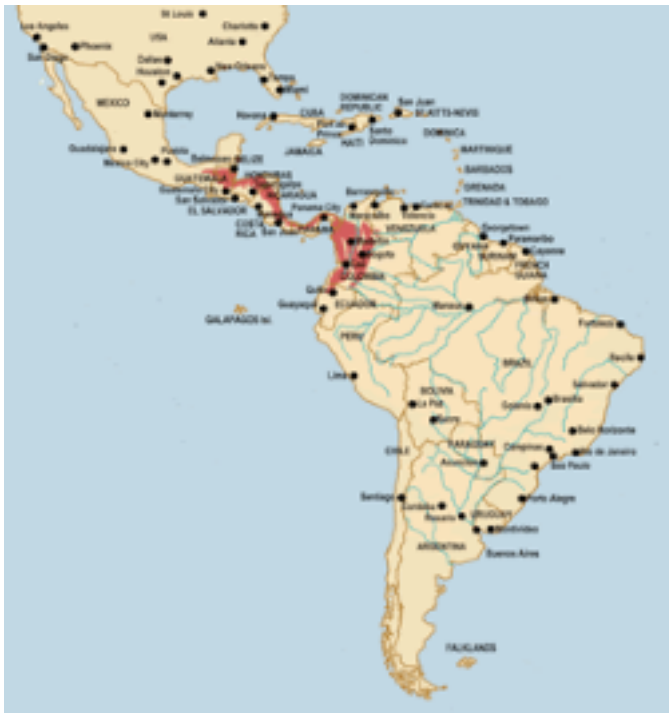
Global region in which snake is found

Central America + South America

CLINICAL OVERVIEW

Eyelash vipers appear to be a significant cause of snakebite within their range and have a reputation for causing quite severe envenoming, local and systemic, with a number of deaths recorded in both adults and children.

Though common in captivity, there are few detailed reports of bites by these snakes. While severe envenoming can occur, it appears likely many bites will cause only mild to moderate envenoming, with principally local effects. Bites should be expected to cause mild to moderate local swelling, pain, possibly minor blistering, but necrosis is likely to be uncommon to rare. In cases with moderate to marked swelling of the bitten limb, major fluid shifts into the bitten limb may occur and secondary shock might develop. There is a potential for at least minor coagulopathy (defibrination, fibrinolysis) and bleeding, with some cases showing persistent bleeding for days after the bite. There is no specific antivenom, but in a severe case, consider the Costa Rican antivenom, which lists this species as being covered.



SNAKEBITE MANAGEMENT OVERVIEW DOCUMENT

SNAKEBITE MANAGEMENT OVERVIEW DOCUMENT (continued)

Bothriechis schlegelii

First aid

1. After ensuring the patient and onlookers have moved out of range of further strikes by the snake, the bitten person should be reassured and persuaded to lie down and remain still. Many will be terrified, fearing sudden death and, in this mood, they may behave irrationally or even hysterically. The basis for reassurance is the fact that many venomous bites do not result in envenoming, the relatively slow progression to severe envenoming (hours following elapid bites, days following viper bites) and the effectiveness of modern medical treatment.
2. The bite wound should not be tampered with in any way. Wiping it once with a damp cloth to remove surface venom is unlikely to do much harm (or good) but the wound must not be massaged.
3. All rings or other jewellery on the bitten limb, especially on fingers, should be removed, as they may act as tourniquets if oedema develops.
4. The bitten limb should be immobilised as effectively as possible using an extemporised splint or sling; if available, crepe bandaging of the splinted limb is an effective form of immobilisation.
5. If there is any impairment of vital functions, such as problems with respiration, airway, circulation, heart function, these must be supported as a priority. In particular, for bites causing flaccid paralysis, including respiratory paralysis, both airway and respiration may be impaired, requiring urgent and prolonged treatment, which may include the mouth to mask (mouth to mouth) technique of expired air transfer. Seek urgent medical attention.
6. Do not use Tourniquets, cut, suck or scarify the wound or apply chemicals or electric shock.
7. Avoid peroral intake, absolutely no alcohol. No sedatives outside hospital. If there will be considerable delay before reaching medical aid, measured in several hours to days, then give clear fluids by mouth to prevent dehydration.
8. If the offending snake has been killed it should be brought with the patient for identification (only relevant in areas where there are more than one naturally occurring venomous snake species), but be careful to avoid touching the head, as even a dead snake can envenom. No attempt should be made to pursue the snake into the undergrowth as this will risk further bites.
9. The snakebite victim should be transported as quickly and as passively as possible to the nearest place where they can be seen by a medically-trained person (health station, dispensary, clinic or hospital). The bitten limb must not be exercised as muscular contraction will promote systemic absorption of venom. If no motor vehicle or boat is available, the patient can be carried on a stretcher or hurdle, on the pillion or crossbar of a bicycle or on someone's back.
10. Most traditional, and many of the more recently fashionable, first aid measures are useless and potentially dangerous. These include local cauterization, incision, excision, amputation, suction by mouth, vacuum pump or syringe, combined incision and suction ("venom-ex" apparatus), injection or instillation of compounds such as potassium permanganate, phenol (carbolic soap) and trypsin, application of electric shocks or ice (cryotherapy), use of traditional herbal, folk and other remedies including the ingestion of emetic plant products and parts of the snake, multiple incisions, tattooing and so on.

SNAKEBITE MANAGEMENT OVERVIEW DOCUMENT

SNAKEBITE MANAGEMENT OVERVIEW DOCUMENT (continued)

Bothriechis schlegelii

Clinical summary

Bites by eyelash vipers are not commonly reported and few detailed clinical data are available, but past regional epidemiology studies suggest this snake is a significant cause of bites, some severe, even fatal, throughout its range. Fatalities have occurred in both adults and children, though the latter are likely at greater risk.

Rates of moderate and major envenoming, compared to minor bites, are not well documented, but it should be assumed that most bites have the potential for severe envenoming, even though many may ultimately prove minor.

From limited case data it appears bites can cause moderate to severe local pain, mild to severe local swelling, with the potential for fluid shifts into the bitten limb and secondary shock, and blistering and oozing from fang marks can occur. Necrosis is certainly a possibility, but it is unclear how frequently it occurs and current data suggests it may be uncommon, even rare. Similarly, if local swelling and tissue injury is severe, compartment syndrome is possible, but incidence is unknown and possibly low.

Systemic effects are possible, but their incidence is unclear. Coagulopathy can occur, with bleeding from IV sites and gums, haematuria, epistaxis, and possibly elsewhere. Without treatment, the coagulopathy may persist for days. Secondary renal failure, though not well documented for this snake, is certainly possible. Neurotoxicity is not expected, but myotoxicity should be considered, based on venom research, although no clinical cases are reported.

SNAKEBITE MANAGEMENT OVERVIEW DOCUMENT

SNAKEBITE MANAGEMENT OVERVIEW DOCUMENT (continued)

Bothriechis schlegelii

Treatment summary

Treatment of bites by the minor pit vipers of Central & South America is similar to that applying to major species, such as some of the *Bothrops* species, except that bites by these generally small pit vipers, unlike the larger *Bothrops* species, is likely to be mild to moderate in most cases. However, more severe envenoming can occur, and may be quite common, at least for the eyelash viper, therefore all cases should be fully assessed and admitted for observation, preferably overnight, to exclude late developing envenoming. Be aware that coagulopathy, if untreated, may persist for several days.

Insert an IV line and give an initial IV fluid load. If there is evidence of major local swelling, with the potential for fluid shifts and shock, monitor BP closely and consider giving further IV fluids to maintain adequate BP and renal perfusion. In such cases, beware later resolution of the swelling resulting in circulatory overload and pulmonary oedema, especially in children. If there is major local swelling look for compartment syndrome. If clinically it appears there may be a developing compartment syndrome, confirm this with pressure measurement before considering fasciotomy, otherwise unnecessary long term limb dysfunction and deformity may well result. Fasciotomy is rarely justified for snakebite. Unless the compartment syndrome is severe and well established, it is usually advisable to first try adequate antivenom therapy before proceeding to fasciotomy. Risks versus benefits must be carefully weighed for each individual case before deciding whether to first give antivenom, or proceed directly to fasciotomy. The latter procedure should only be used as a last resort and only if there is no active, major coagulopathy. In general, it is better to use antivenom to control local effects, rather than surgical intervention. Perform blood tests, looking particularly for coagulopathy. If initially normal, repeat 1-2x over several hours, to exclude late developing problems. Monitor renal function and fluid balance.

For cases with significant local or systemic envenoming, it is appropriate to consider antivenom therapy. The choice of antivenom for eyelash viper bites will depend on availability, but where several choices are available, the one most specific, taxonomically or geographically, is the first choice. Only the Costa Rican antivenom states it is specific for eyelash viper envenoming (though this species is not in the immunising mix), but several other antivenoms may give at least some cross protection (none state they do, however). Give antivenom IV, with adrenaline & resuscitation equipment ready, in case of an adverse reaction. The initial dose will depend on the antivenom being used and the severity of the bite. For the Costa Rican antivenom, an initial dose of at least 5 vials is appropriate, but severe cases may require considerably more. Be prepared to give further doses, if the initial dose fails to give an adequate response after 3+ hours.

The Mexican antivenom, Antivipmyn might also be considered, if the Costa Rican product is unavailable, though note that the producer, Bioclon, does not list the eyelash viper as covered and there is no certainty it will be effective. However, a higher initial dose is likely to be required, at least 10-12 vials (producer, Bioclon, suggests 5-16 vials initially in adults, depending on severity, with double this dose in children), and further doses may be needed to neutralise all circulating venom. The indication for further doses is unclear, but consider worsening local swelling or effects, or worsening or developing systemic effects, especially coagulopathy. Note that while this antivenom has been recommended for use in North American snakebite, it has only rarely been used in this role and does not yet have US FDA approval; the immunising snake species are central-south American, not North American.

In general, if there is a major coagulopathy or bleeding, antivenom will be the most effective treatment and should always be tried first, before considering blood product replacement therapy, except if there is life-threatening bleeding. If antivenom in adequate amounts fails to reverse coagulopathy sufficiently, over a reasonable period of time (allow several hours for such an effect, not minutes), then replacement therapy may be considered. Depending on the nature of the clinical problem or lab test abnormality, FFP, cryoprecipitate, platelet concentrate or whole blood might all be considered.

It is also unclear if antivenom will reduce the extent of systemic myolysis, should this occur (uncertain for eyelash viper bites), but limited experience elsewhere suggests it may be effective. As severe myolysis is potentially lethal and debilitating, it is appropriate to trial antivenom therapy to reduce myolysis. Substantial doses might be required, but exact amounts are not currently determined.

All patients receiving antivenom or suffering any significant local or systemic effects should be followed up after discharge, particularly looking for delayed reactions to the antivenom (serum sickness) and functional problems affecting the bitten limb, as a result of venom-induced tissue injury, as well as secondary infection. The latter is possible, though probably uncommon, so prophylactic antibiotics are not appropriate. Some experts suggest that a short course of prophylactic oral steroids may reduce the incidence of serum sickness, but this remains unproven. It should be stressed that even with the best treatment possible, full pre-injury function and appearance of the bitten limb cannot be guaranteed. Therefore, any such defect is not automatically an indication of malpractice, nor should it occasion legal action by the patient. It is best to advise patients/relatives from the outset that snakebite is a potentially severe injury, with a potential for adverse outcomes beyond the control of modern medical practice. Honest early discussion of the potential short and long term risks of both the bite and its treatment (ie anaphylactoid or serum sickness reactions to antivenom) are in the interests of both the patient and those offering treatment and may reduce the chance of later dissatisfaction or litigation.

STATE TOXINOLOGY SERVICES

Toxinology Dept., Women's & Children's Hospital, North Adelaide SA 5006 AUSTRALIA

SNAKEBITE MANAGEMENT OVERVIEW DOCUMENT

Few doctors see snakebite cases frequently. Unless the treating doctors see many cases and feel justifiably confident in treating envenoming, they should consider early discussion with colleagues expert in this area of medicine. Such expert advice may be available through the regional poisons centre, who will likely have a list of on-call experts. Early consultation may well avoid unpleasant problems developing later.

STATE TOXINOLOGY SERVICES

Toxinology Dept., Women's & Children's Hospital, North Adelaide SA 5006 AUSTRALIA

SNAKEBITE MANAGEMENT OVERVIEW DOCUMENT

SNAKEBITE MANAGEMENT OVERVIEW DOCUMENT (continued)

Bothriechis schlegelii

Available antivenoms

Polyvalent Antivenom
Instituto Clodomiro Picado T.
Facultad de Microbiología
Universidad de Costa Rica
San Pedro, San Jose
Central America
Costa Rica
Phone: ++506-229-0344; ++506-229-3135
Fax: ++506-292-0485
Email: fchaves@cariari.ucr.ac.cr
Website: www.icp.urc.ac.cr/comentar.htm

STATE TOXINOLOGY SERVICES

Toxinology Dept., Women's & Children's Hospital, North Adelaide SA 5006 AUSTRALIA

SNAKEBITE MANAGEMENT OVERVIEW DOCUMENT

SNAKEBITE MANAGEMENT OVERVIEW DOCUMENT (continued)

Bothriechis schlegelii

Management Flowchart

